



Physicians Caring for Texans

TexMed 2017 Clinical Abstract

Please complete all of the following sections and include supporting charts and graphs in this document. Submit a total of two documents - this document and the Biographical Data and Disclosure Form to posters@texmed.org by midnight March 31, 2017.

Procedure and Selection Criteria

- Submissions not directly related to quality improvement or research may be accepted and should follow the standardized format outlined below. Content should enhance knowledge in the field of clinical care and be relevant to a given patient population.

PROJECT NAME: Use of Ultrasound Guidance for Safe Intra-arterial Chemotherapy for Infant Retinoblastoma

Institution or Practice Name: Retina Consultants of Houston, Memorial Hermann Hospital & University of Texas Health Science Center at Houston

Setting of Care: Retina Consultants of Houston and Memorial Hermann Hospital, Houston, TX.

Primary Author: Ryan Kim, BA

Secondary Author: Amy Schefler, MD

Other Members of Project Team: Mark Dannenbaum, MD, Michael Lin, MD, Deborah Brown, MD, Maria E. Bretana, CDOS

Is the Primary Author, Secondary Author or Member of Project Team a TMA member (required)?

Yes No

Please provide name(s) and their role in the project: Ryan Kim (medical student researcher), Amy Schefler, MD (Principal Investigator)

TMA Member Name: Ryan Kim, BA, Amy Schefler, MD

TexMed Poster Session Specialty Subject Area: Please check if these apply.

Enhanced Perioperative Recovery

Disaster Medicine and Emergency Preparedness

Clinical

Background (15 points max): Describe the purpose for sharing the content. What caused this subject matter to be approached? Why is this content important to share? What is the potential impact if this content is not shared?

Retinoblastoma is the most common primary ocular cancer in pediatric population, with approximately 300 new cases reported every year in the U.S. For the past many decades, primary intervention for retinoblastoma was mostly enucleation, external beam radiotherapy, or systemic chemotherapy. However, a new chemotherapy technique of locally injecting chemotherapeutic agents at the ostium of the ophthalmic artery of the affected eye using modern microcatheters has revolutionized the treatment of retinoblastoma and has drastically increased the eye salvage rate from 5% to 95%. Since the implementation of this new treatment modality about ten years ago, research has focused on lowering the age requirement for intra-arterial chemotherapy

(IAC). Studies have found that younger patients with treatment-naïve eyes may respond better to fewer doses of chemotherapy than their older counterparts. One of the major challenges of administering IAC in small infants (<10 kg) is procedural complications such as femoral hematoma due to the small, underdeveloped vasculature of the patients. For this reason, IAC is often reserved until patients reach a certain age or weight threshold. At our center, an experienced neuro-interventionalist uses ultrasound guidance as part of our IAC regimen, and we have not observed any procedural complications for our IAC cases. In this pilot study of six patients under 10 kg with retinoblastoma, we have demonstrated that ultrasound guidance for femoral artery catheterization ensures extra safety during IAC procedure. The goal of this research is to encourage more centers to become more comfortable with IAC even in patients less than 10 kg if they are great candidates otherwise for IAC.

Intended Stakeholders (15 points max): *Identify those individuals, organizations, or interest groups that could be potentially impacted by this information or benefit by obtaining this information.*

This research mostly impacts pediatric patients who have retinoblastoma, their primary ocular oncology care providers, as well as anyone who is interested in the management of cancer. A significant portion of retinoblastoma patients are still treated with systemic chemotherapy or with IAC at an older age, whereas more studies are showing benefits of earlier clinical intervention with IAC. If procedural complications can be minimized for the very small infants that are under 10 kg, we may treat even smaller infants with IAC and consequently improve oncologic efficacy of IAC even further. There are very few reports on the topic of weight at the time of first IAC for retinoblastoma, and our study contributes a unique perspective on demonstrating the safety of IAC for children under 10 kg when ultrasound guidance was utilized.

Description of Accomplished Work (25 points max): *Provide an overview of the work that was accomplished, including any specific methods, tools or techniques. Also, include any milestones or key accomplishments. Note charts, graphs and tables here and send as addendum with abstract form.*

A total of six retinoblastoma patients (2 male and 4 female) that were under 10 kg at the time of the first IAC were included in this retrospective, observational consecutive series. Five patients had bilateral retinoblastoma, and one had unilateral retinoblastoma. One eye was classified as International Classification of Retinoblastoma Group B, while 4 were Group C and 6 were Group D. Median age at first IAC was 8.4 months, while the median weight at first IAC was 9.2 kg (ranging from 7.5 kg to 9.6 kg).

For all patients, femoral arterial access was achieved using a micropuncture kit and ultrasound guidance. Standard 4 Fr microcatheter and digital subtraction angiography were used for chemotherapeutic injection at the ostium of the ipsilateral ophthalmic artery. A total of 59 intra-arterial chemotherapeutic injections were administered with 100% successful catheterization rate. Melphalan (1.5-5.0 mg), topotecan (0.3-2.0 mg), and/or carboplatin (30-40mg) were used based on each patient's treatment history. Mean number of IAC cycles per eye was 3 (range, 1-7 times). All eyes were salvaged, and no eyes were lost to enucleation or external beam radiation therapy.

Mean follow-up for this study was 21.4 months (range, 13.1 – 34.5 months), and adjuvant therapies including diode laser, cryotherapy, or intra-vitreous melphalan injection were provided during follow-up if necessary. One patient experienced a transient loss of pulse due to vasospasm after IAC but readily recovered in the post-anesthesia care unit. A total of 13 episodes of neutropenia (grades 2-4) occurred in 4 patients, and 3 episodes of bronchospasm were reported. There were 3 episodes of tumor recurrence that were successfully managed with adjuvant therapies. No metastases have been reported to date. One episode of temporary supratrochlear rash, eyelid edema, neutropenic fever, transient vitreous hemorrhage, and neovascular glaucoma was each reported and successfully treated or resolved spontaneously.

Femoral artery diameter was measured retrospectively by two independent observers, yielding a median diameter of 3.74 mm (range, 2.66 mm – 4.77 mm). Considering that a 4 Fr catheter has a diameter of 1.33 mm, the use of ultrasound guidance for femoral artery access ensured safe entry into the small femoral arteries of the study patients.

Timeframe and Budget (20 points max): Provide the start and end dates for the work along with any financial implications that were incurred due to the work accomplished. Note charts, graphs and tables here and send as addendum with abstract form.

This study included patients that were treated with IAC at our center between April 2014 and March 2016. Data analysis was conducted from May 2016 and completed by December 2016. No external funding was provided for this study.

Intended Use (25 points max): Describe how this information could be used moving forward to impact patient care.

This project provides evidence that the use of ultrasound guidance for femoral artery access can further enhance the safety of IAC procedure for very small infants that are under 10 kg. Even though there exists scientific literature that infants as small as 2 months old with retinoblastoma can successfully be treated with IAC, most centers do not perform IAC until patients reach a certain weight and age threshold in order to prevent procedural complications. In our study, ultrasound guidance served as an extra safety measure that yielded zero procedural complications. Our study demonstrates that as few as one to three IAC cycles can adequately lead to full regression of retinoblastoma in treatment-naïve eyes in the youngest children. Further prospective studies focusing on the weight limit and administration of IAC to young, treatment-naïve eyes can bring forth a new standard of care.

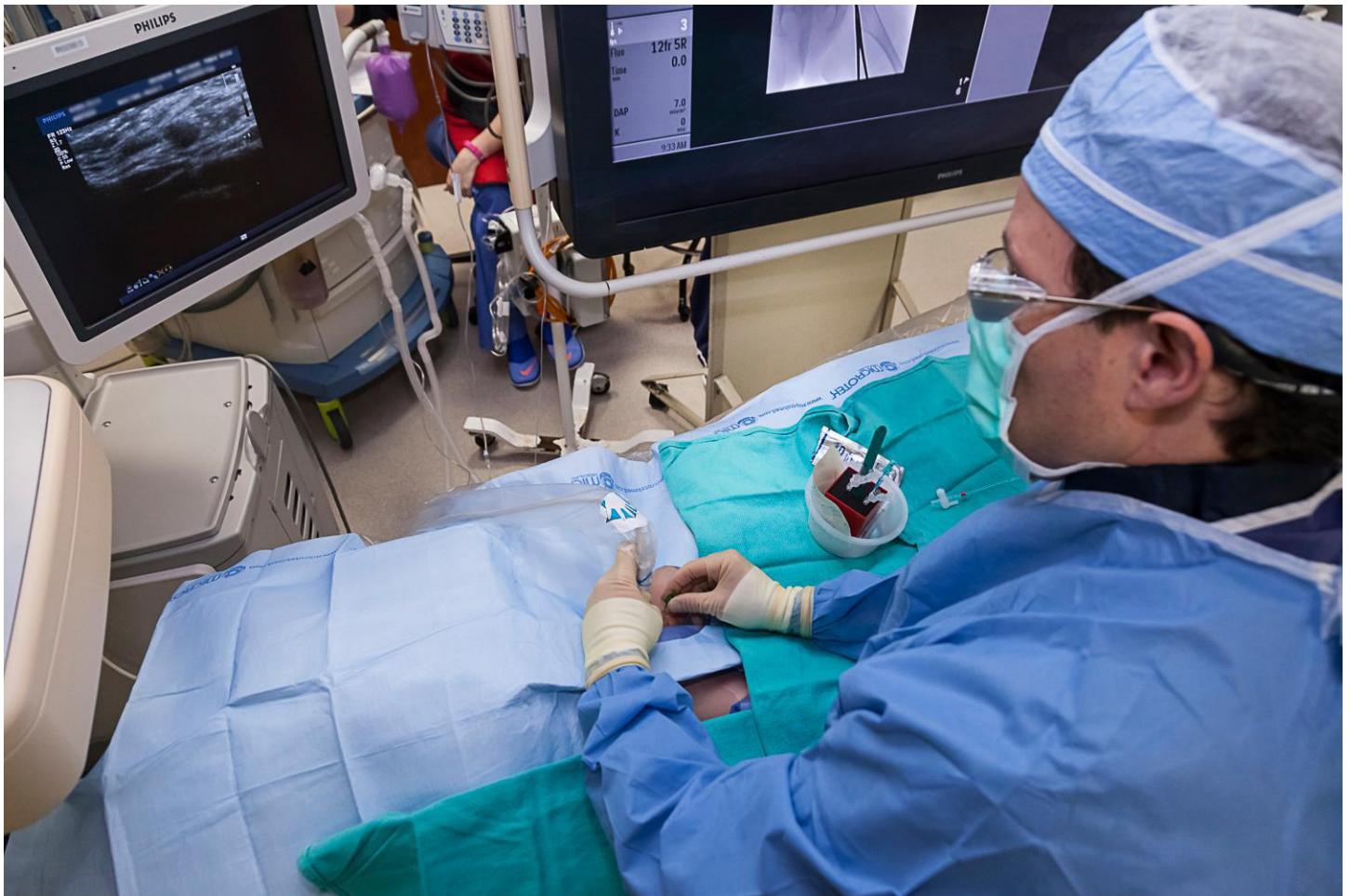

Figure 1. Image of a neuro-interventionalist accessing the femoral artery using ultrasound guidance and standard micropuncture kit.

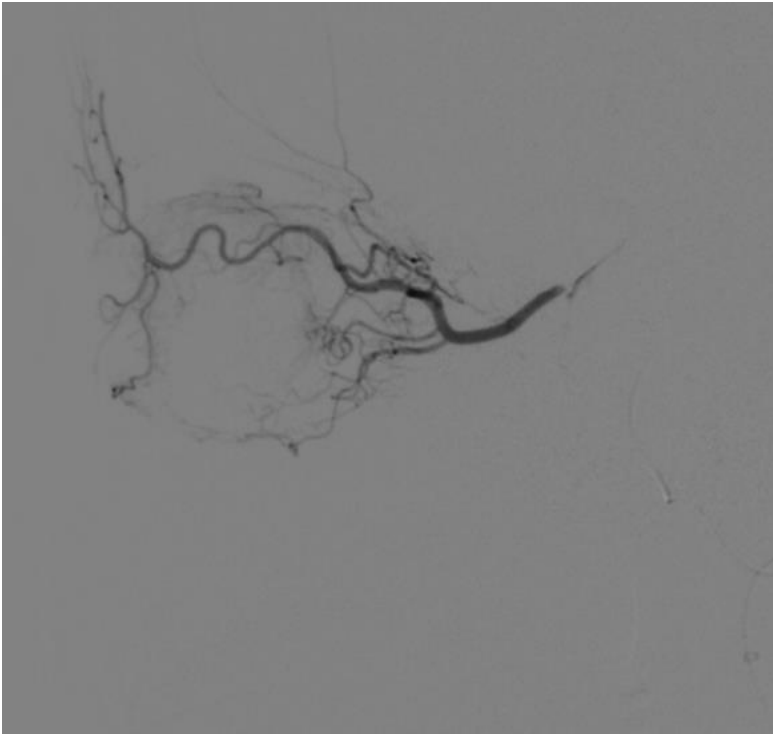


Figure 2. Super-selective microcatheter injection that demonstrates opacification of the left ophthalmic artery. Lateral View.